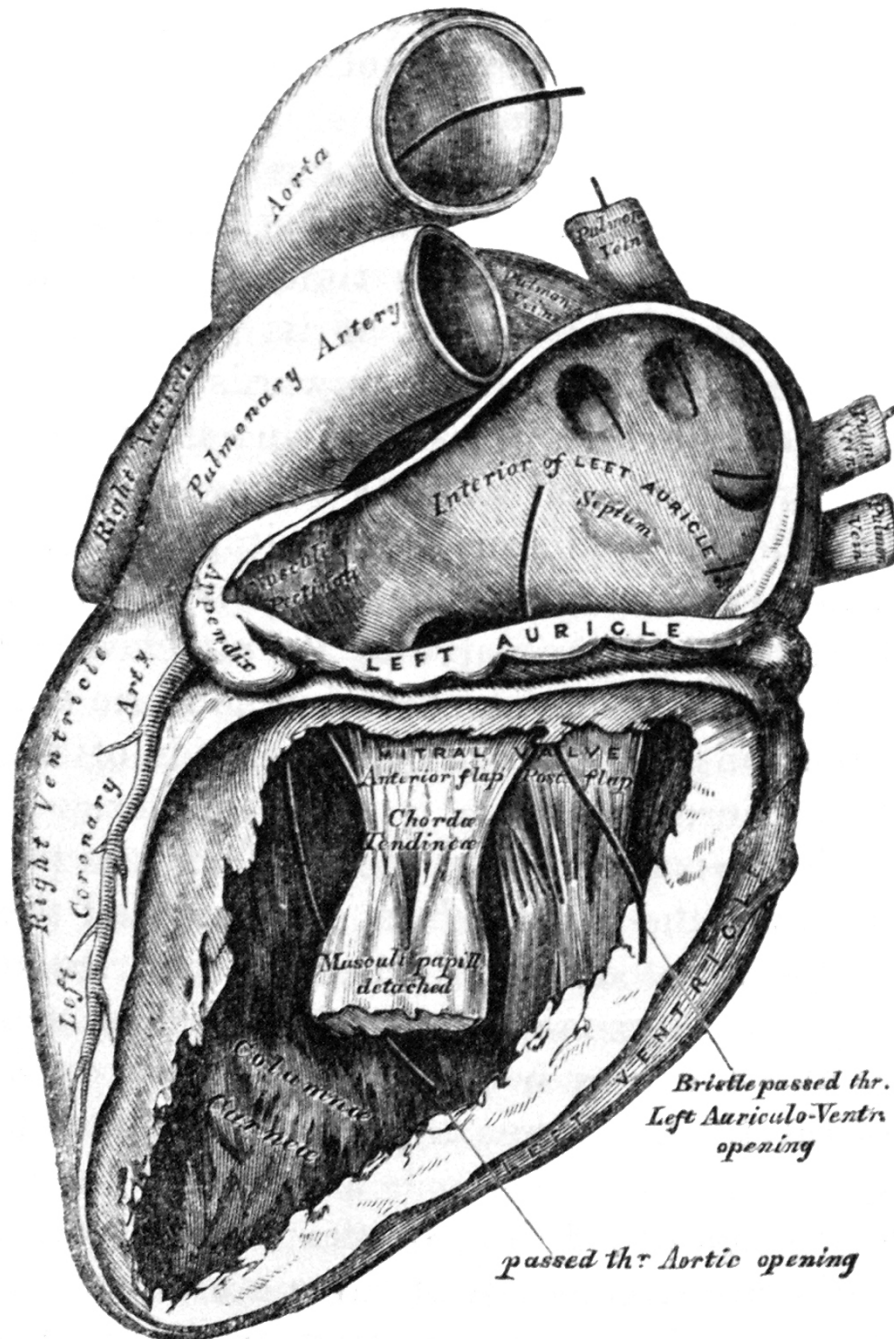
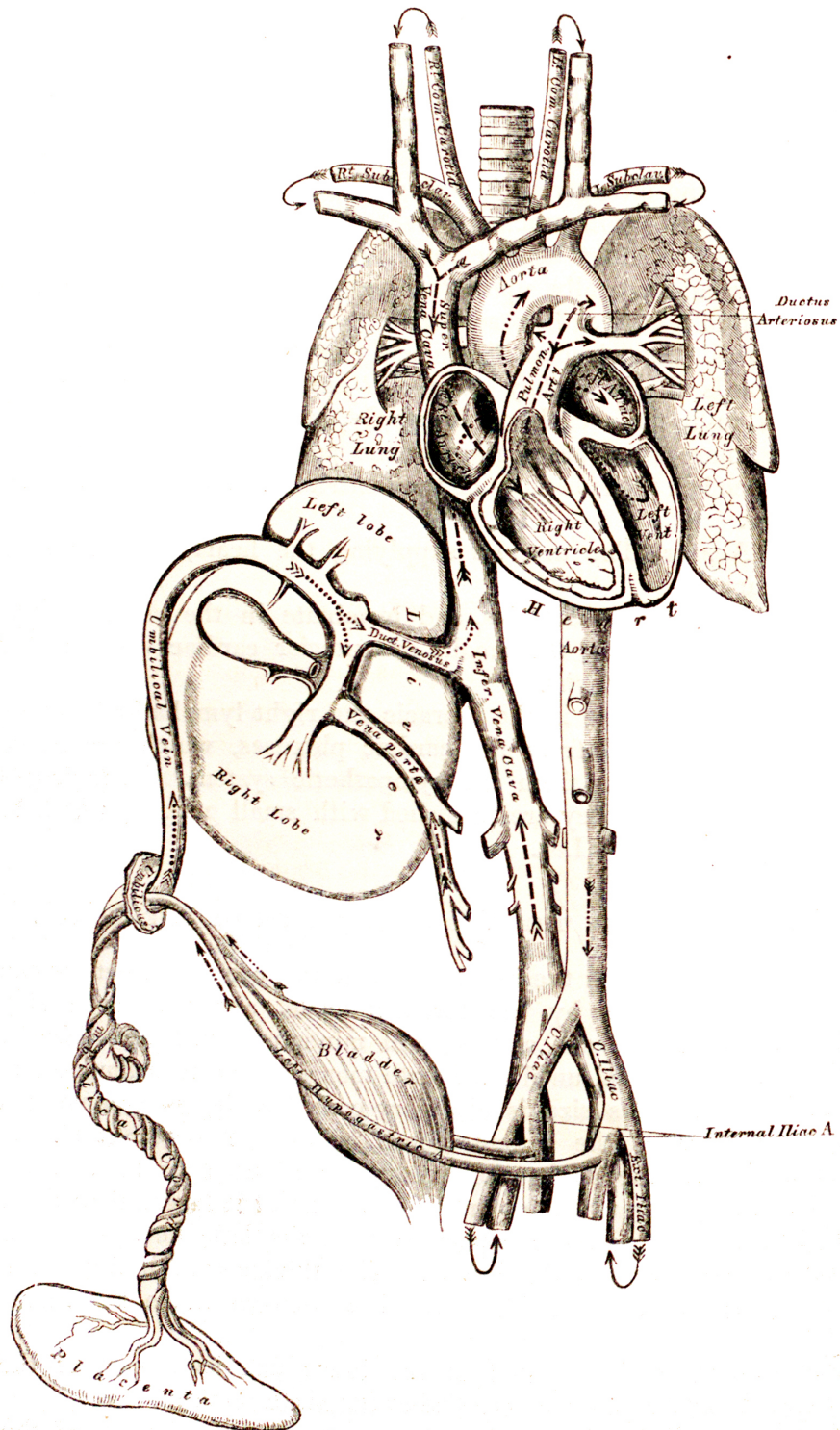




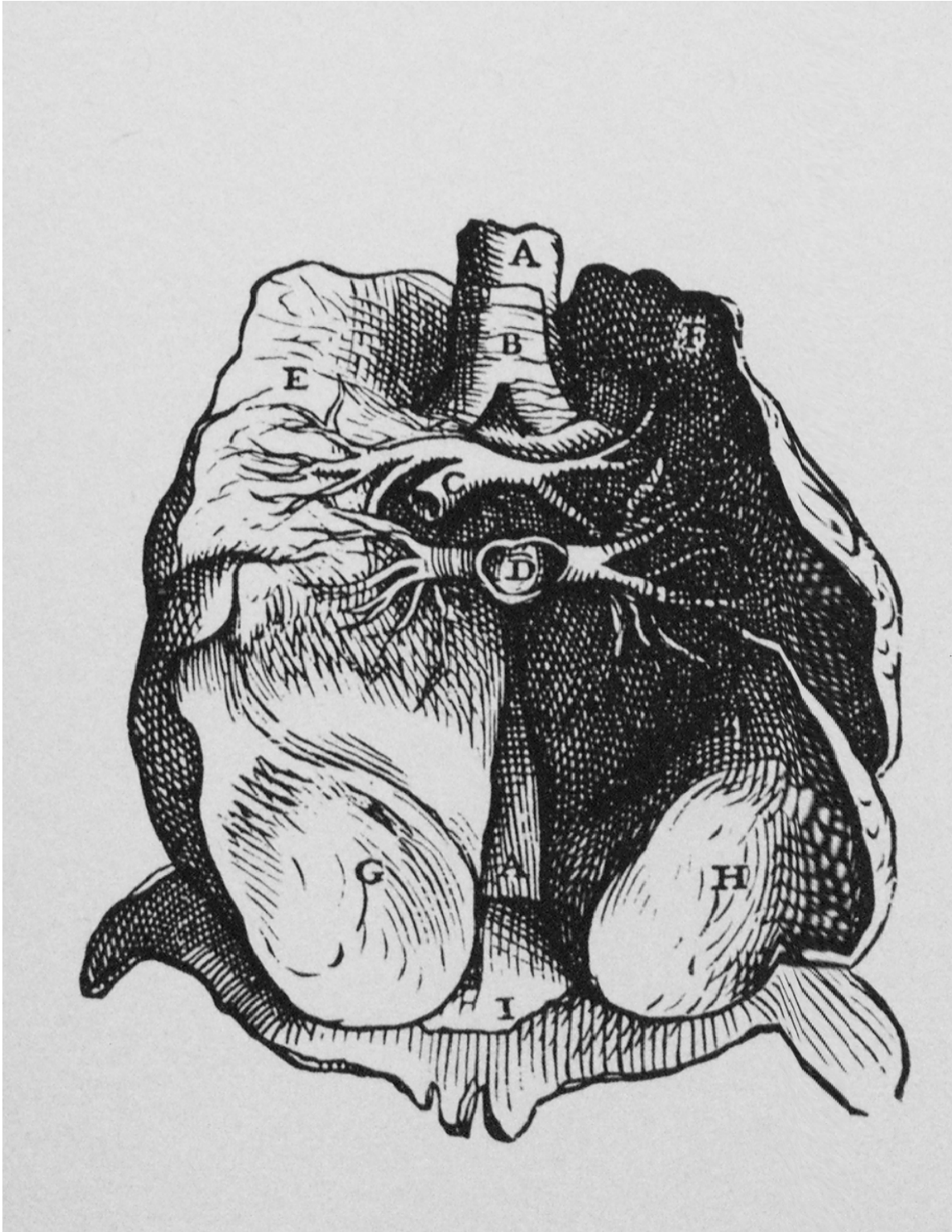
329.—The Left Auricle and Ventricle laid open, the Anterior Walls of both being removed.



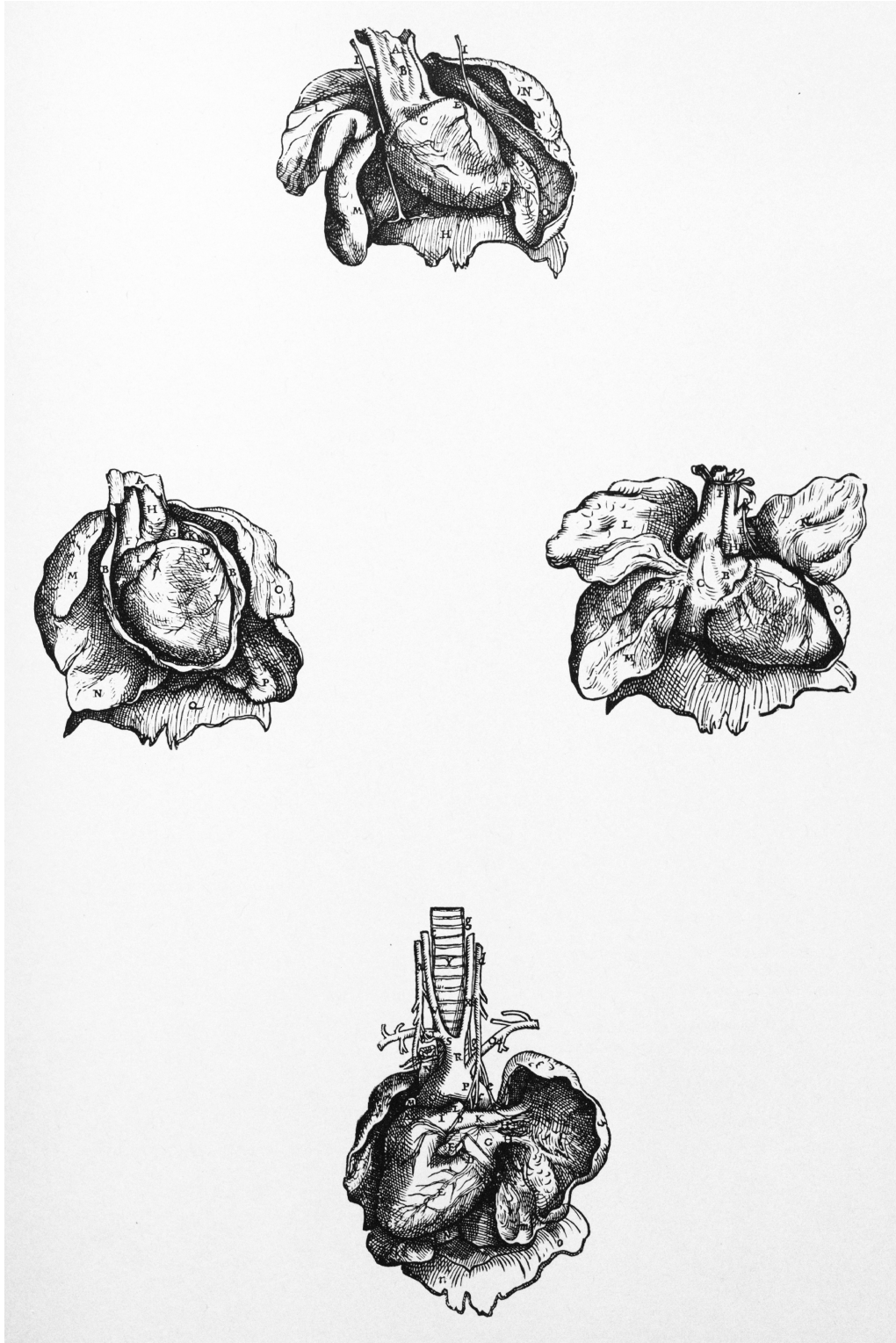
Gray's Anatomy Left Auricle and Ventricle. Gray, Henry, and H. V. Carter. Anatomy, Descriptive and Surgical. London: J.W. Parker, 1858.



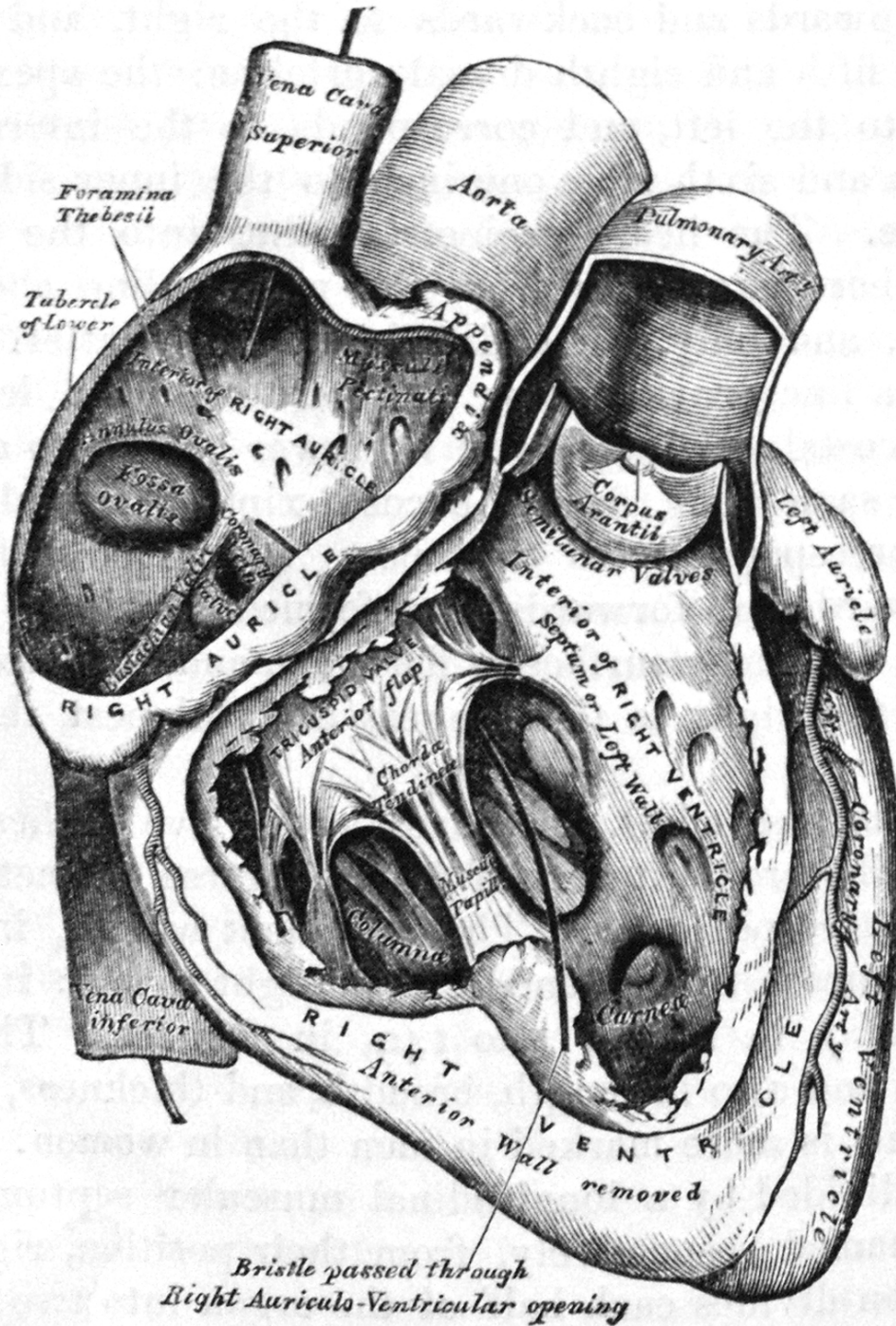
Gray's Anatomy Fetal Circulation. Gray, Henry, and H. V. Carter. Anatomy, Descriptive and Surgical. London: J.W. Parker, 1858.



Vesalius, Andreas, J. B. de C. M Saunders, and Charles Donald O'Malley. *The Illustrations From the Works of Andreas Vesalius of Brussels: With Annotations and Translations, a Discussion of the Plates and Their Background, Authorship and Influence, and a Biographical Sketch of Vesalius*. Cleveland: World Pub., 1950.



Vesalius, Andreas, J. B. de C. M Saunders, and Charles Donald O'Malley. *The Illustrations From the Works of Andreas Vesalius of Brussels: With Annotations and Translations, a Discussion of the Plates and Their Background, Authorship and Influence, and a Biographical Sketch of Vesalius*. Cleveland: World Pub., 1950.



and internally, with the left auricle, being free in the rest of