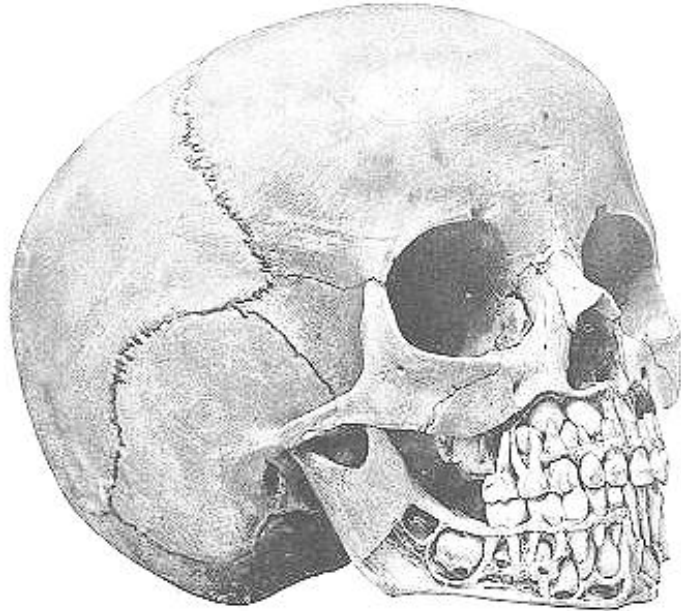


MEDICAL HERITAGE LIBRARY
2018 Color Our Collections



Coloring Book

FIG. 29.



Skull of a child about six years old, showing all the deciduous teeth in position and the developing permanent ones.

From *Studies of the internal anatomy of the face*
(<https://archive.org/details/studiesofinterna00crye>)

M.H. Cryer (1901)
Columbia University Libraries



From *Hog's Eye and Human* (<https://archive.org/details/hogseyehuman00marg>)
Margaret Prescott Montague (1927)
American Printing House for the Blind, Inc.; M.C. Migel Library

OUTLINES OF PHRENOLOGY,

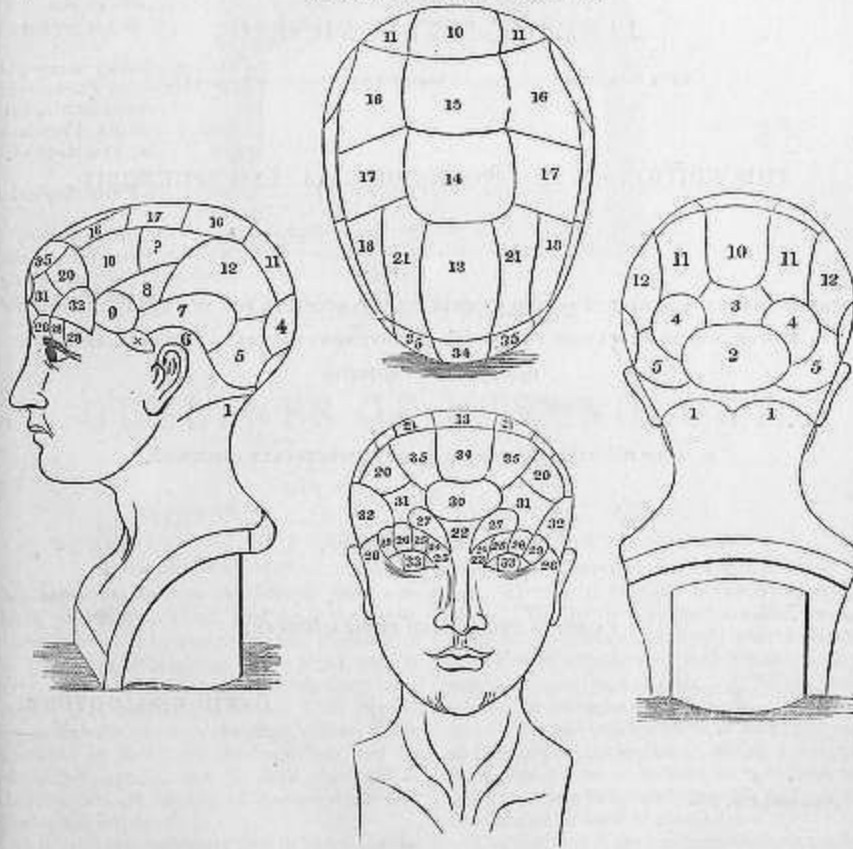


BY THE LATE J. G. SPURZHEIM, M.D.,

OF THE UNIVERSITIES OF VIENNA AND PARIS, AND LICENCIATE OF THE ROYAL COLLEGE OF PHYSICIANS OF LONDON.

REVISED AND REPRINTED FROM THE FOURTH AMERICAN EDITION, PUBLISHED AT BOSTON, 1836.

SECOND ENGLISH EDITION.



GLASGOW:

PUBLISHED BY J. & G. GOYDER, PHRENOLOGICAL INSTITUTION,
104, BRUNSWICK STREET;

J. MENZIES, EDINBURGH; MACHEN & CO., DUBLIN;

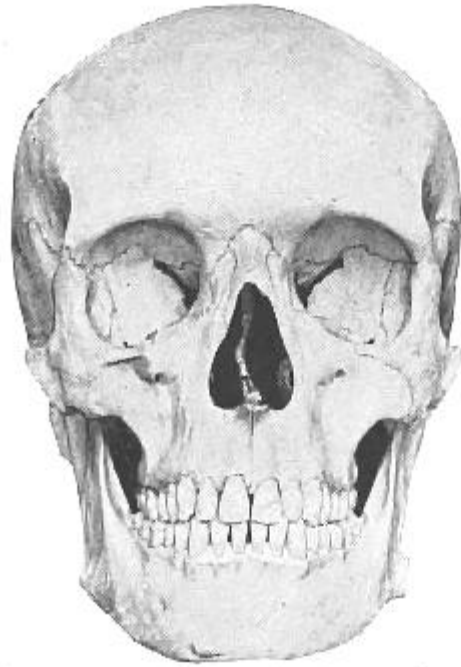
J. S. HODSON, 112, FLEET STREET, & Wm. NEWBURY, 6, KING STREET, HOLBORN, LONDON;
AND OTIS CLAPP, BOSTON, U.S.

MDCCLXIV.

From *Outlines of phrenology* (<https://archive.org/details/b24917679>)

J G Spurzheim (1844); University of Glasgow Library

Fig. 24



Anterior view of the typical skull shown in Fig. 22

From *Studies of the internal anatomy of the face*
(<https://archive.org/details/studiesofinterna00crye>)

M.H. Cryer (1901)
Columbia University Libraries

many probably still less conspicuous, inflammatory processes can spread from the surface to the interior of the skull. Thus we find such affections as

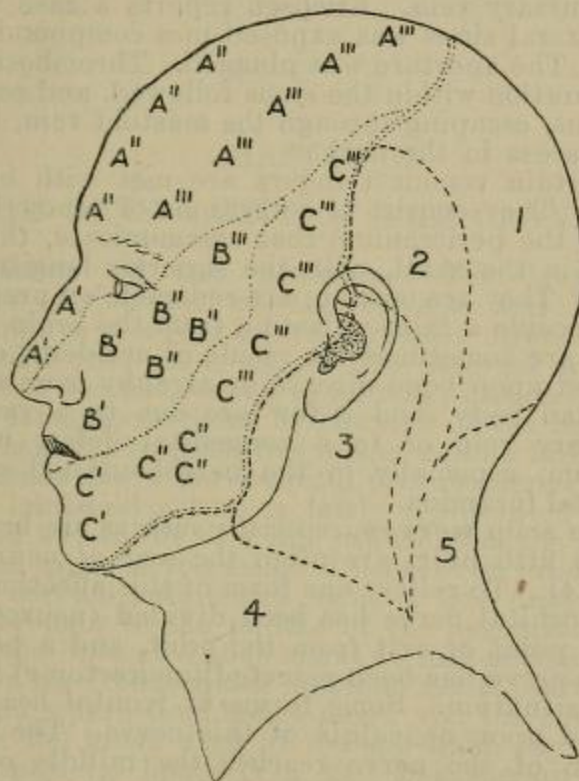


Fig. 4.—Nerve areas of the face and scalp.

A, A, Distribution of the first division of the fifth cranial nerve; A', nasal branch; A'', supratrochlear; A''', supraorbital.
B, B, distribution of the second division; B', infraorbital branch; B'', malar branch; B''', temporal branch.
C, C, distribution of the third division; C', mental branch; C'', buccal branch; C''', auriculo-temporal.
1, area of great occipital; 2, of small occipital; 3, of great auricular; 4, of superficial cervical; 5, of third occipital.

erysipelas of the scalp, diffuse suppuration of the scalp, necrosis of the cranial bones, and the like, leading by extension to mischief within the diploë, to thrombosis of the sinuses, and to inflammation

From *Surgical applied anatomy* (<https://archive.org/details/surgicalapplieda1907trev>)

Sir Frederick Treves (1907)
Columbia University Libraries



From *The flowering plants and ferns of Great Britain Volume I*
(https://archive.org/details/b28107743_0001) Anne Pratt (1855)
Society for Promoting Christian Knowledge; The Wellcome Library



SCARLET PIMPERNEL

From *Wild flowers* Volume I (https://archive.org/details/b28121338_0001)
Anne Pratt, 1893
Wellcome Library

The Medical Heritage Library (MHL), a digital curation collaborative among some of the world's leading medical libraries, promotes free and open access to quality historical resources in medicine. Our goal is to provide the means by which readers and scholars across a multitude of disciplines can examine the interrelated nature of medicine and society, both to inform contemporary medicine and strengthen understanding of the world in which we live. The MHL's growing collection of digitized medical rare books, pamphlets, journals, and films number in the tens of thousands, with representative works from each of the past six centuries, all of which are available here through the Internet Archive.

Find Us At...

...Our blog:

www.medicalheritage.org

...Our Twitter:

[@medicalheritage](https://twitter.com/medicalheritage)

...Our Facebook:

[/medicalheritagelibrary](https://www.facebook.com/medicalheritagelibrary)

...Our collections:

<http://www.archive.org/details/medicalheritagelibrary>

<https://archive.org/details/statemedicalsocietyjournals>

Credits

Cover: Cover coloring by Catherine Pate who was having fun with Photoshop.